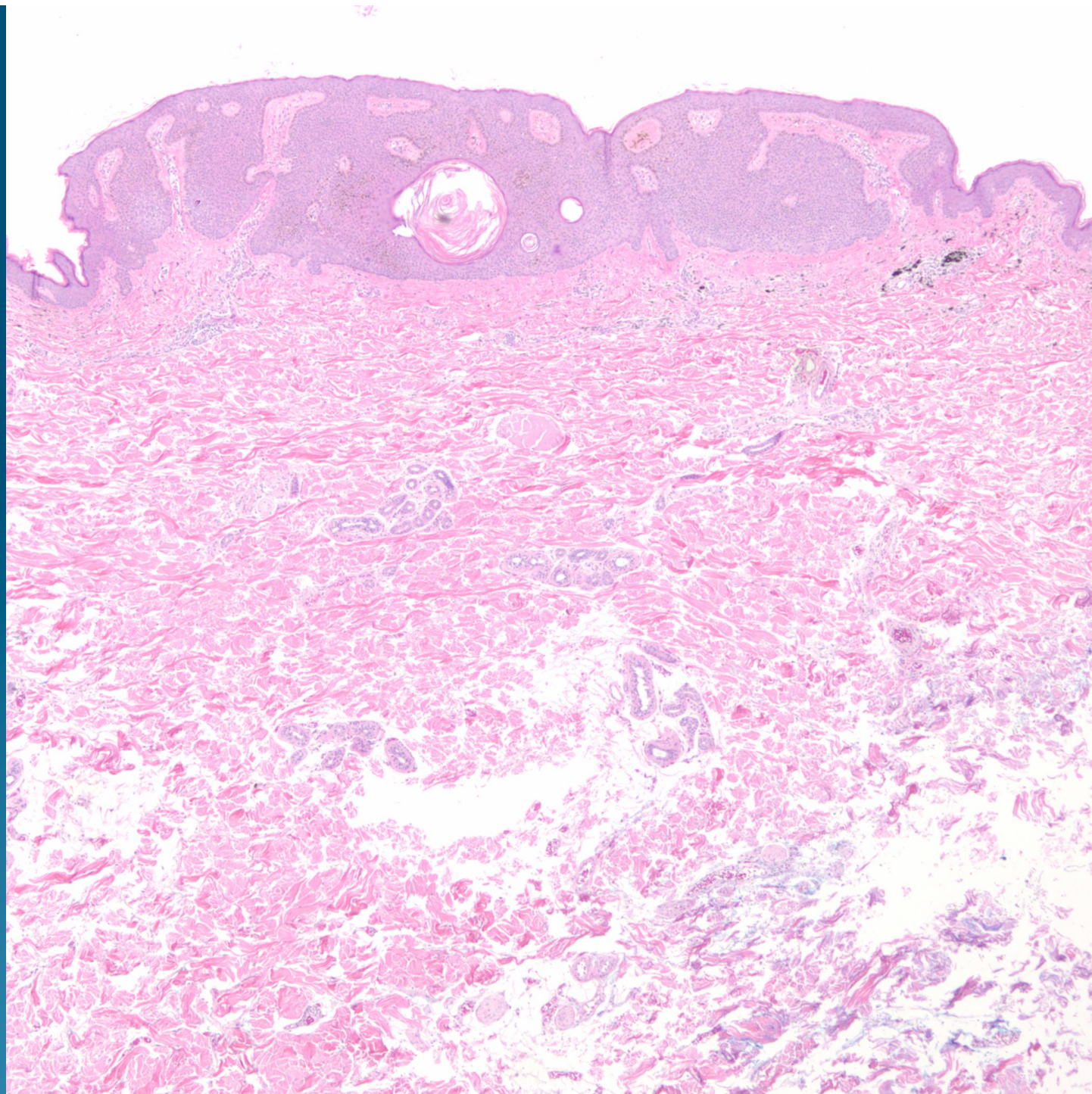
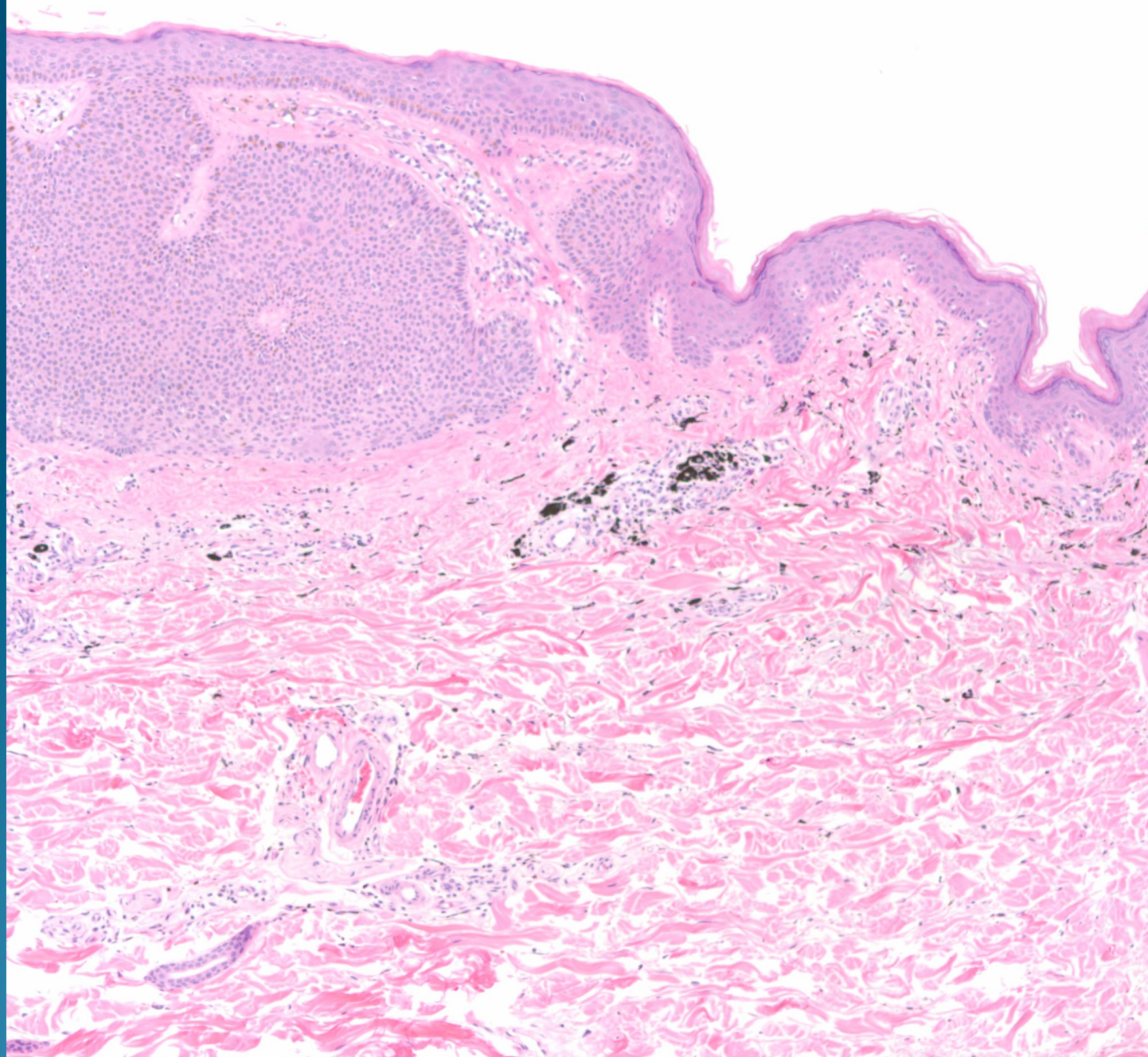
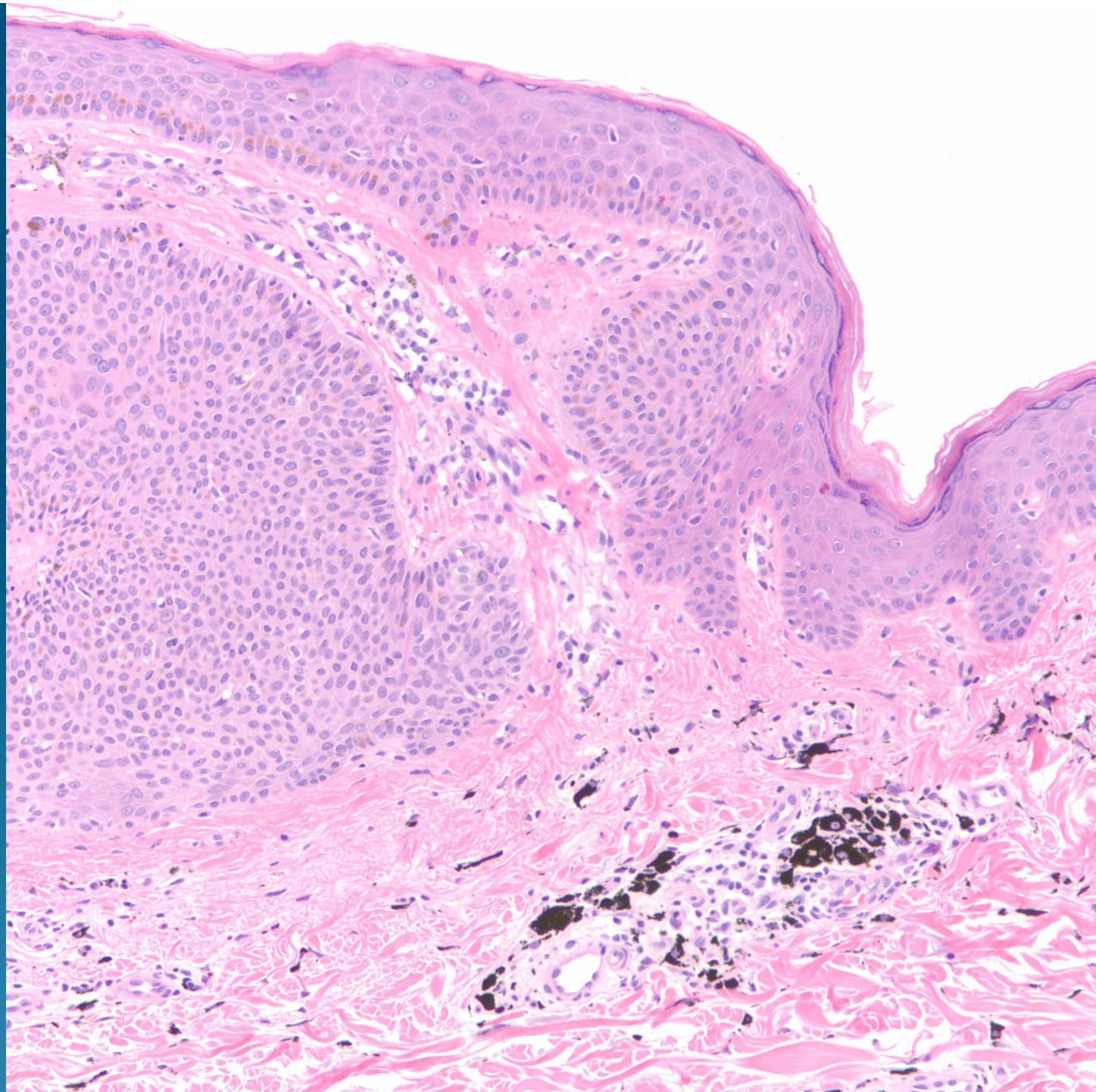


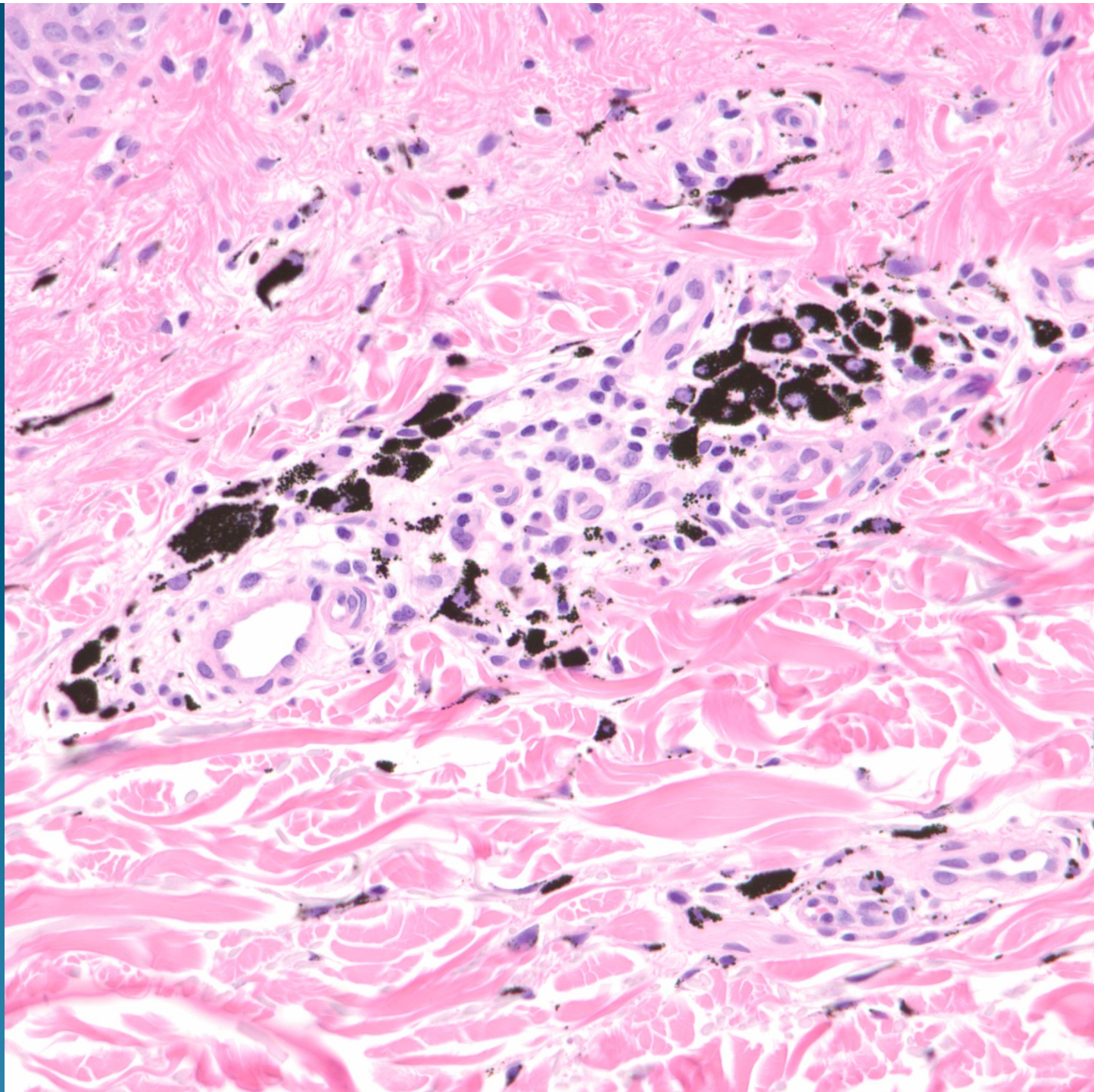
# Dermatopathology Slide Review Part 76

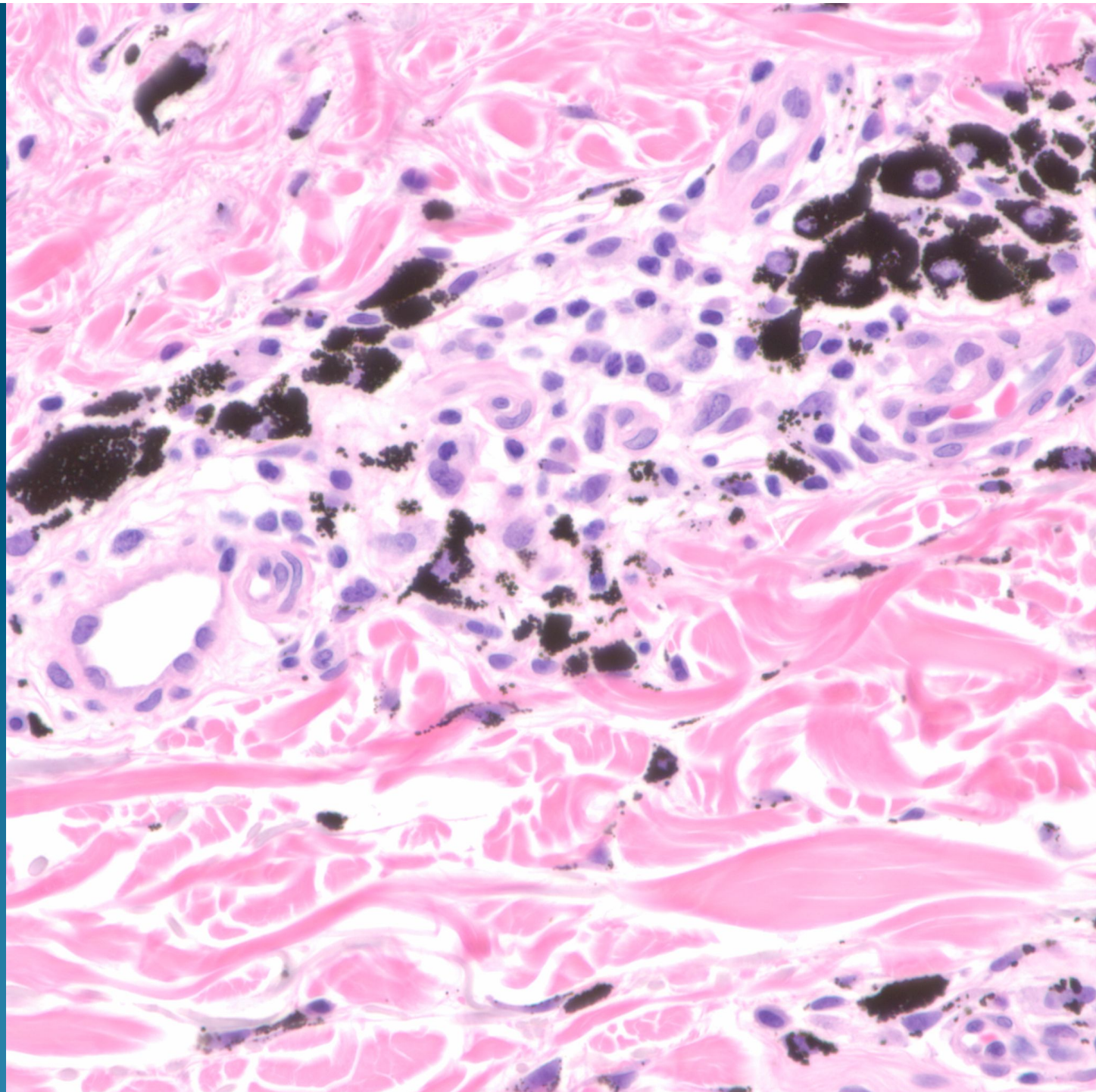
Paul K. Shitabata, M.D.  
Dermatopathology Institute









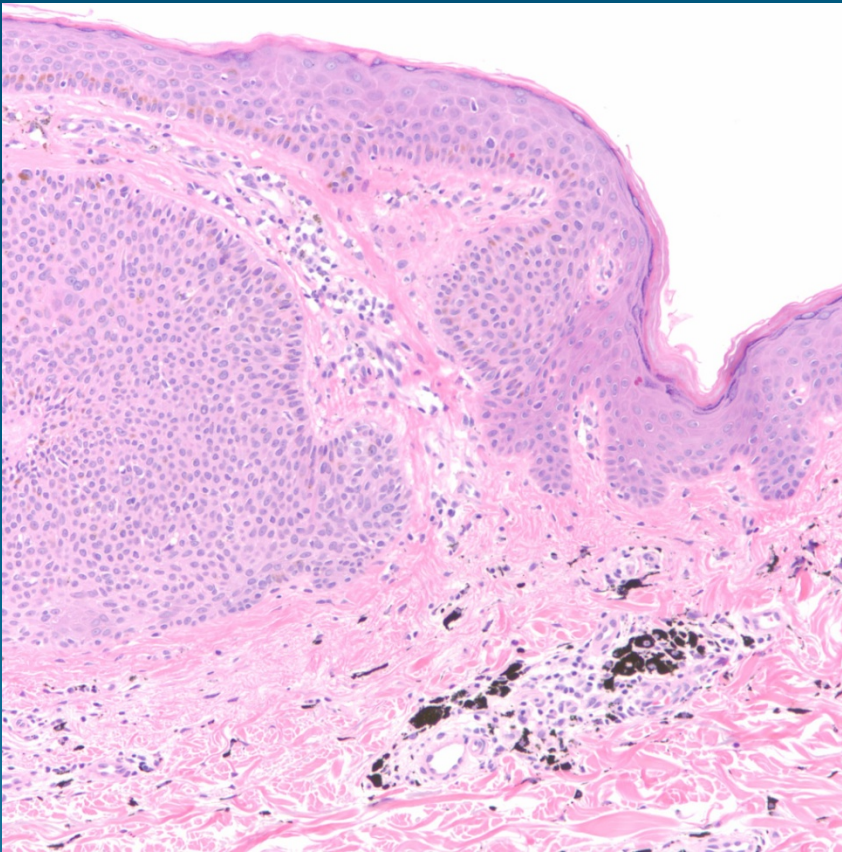


# What is the best diagnosis?

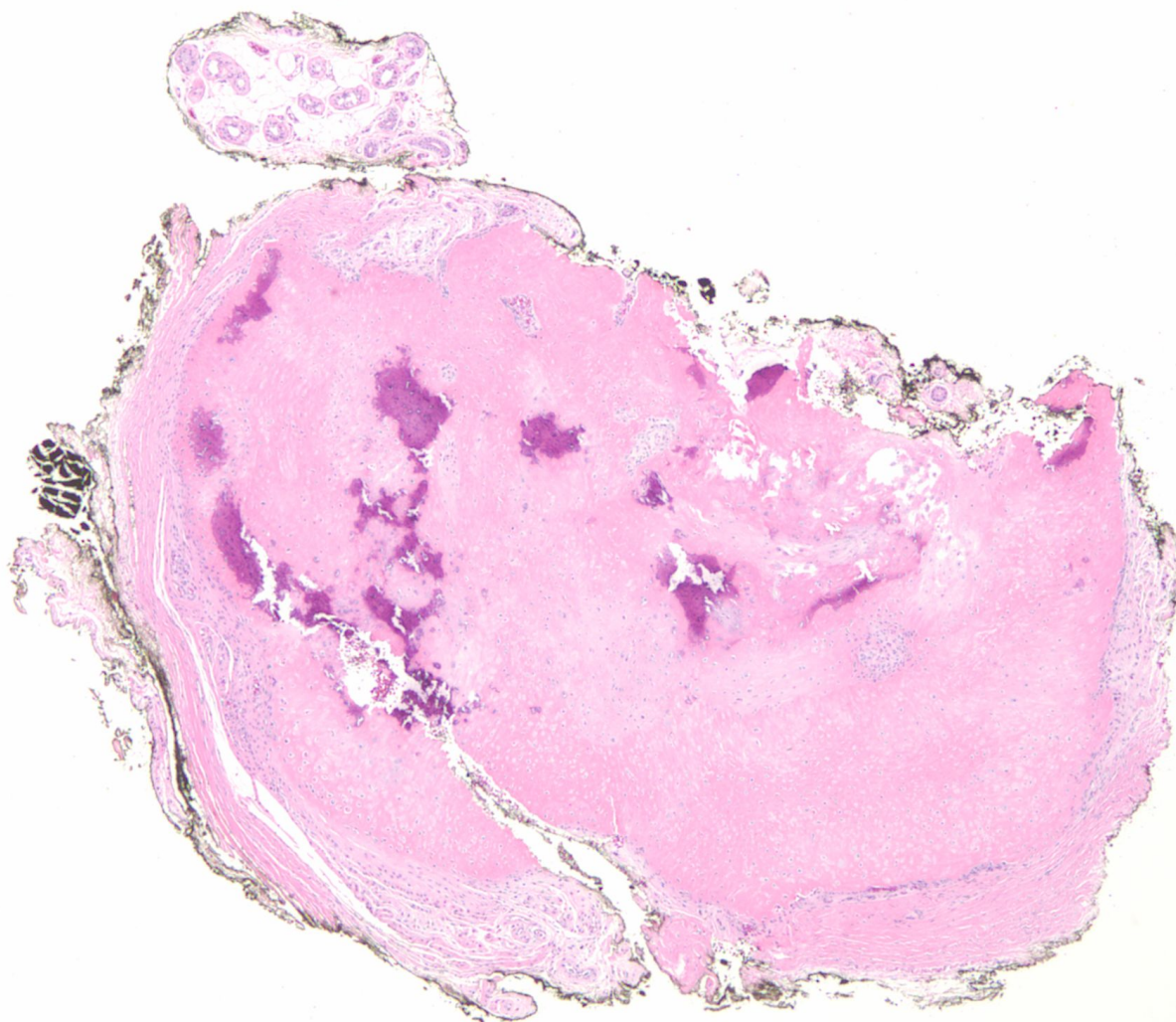
- A. Blue nevus
- B. Mongolian spot
- C. Tattoo
- D. Desmoplastic melanoma
- E. Combined melanocytic nevus

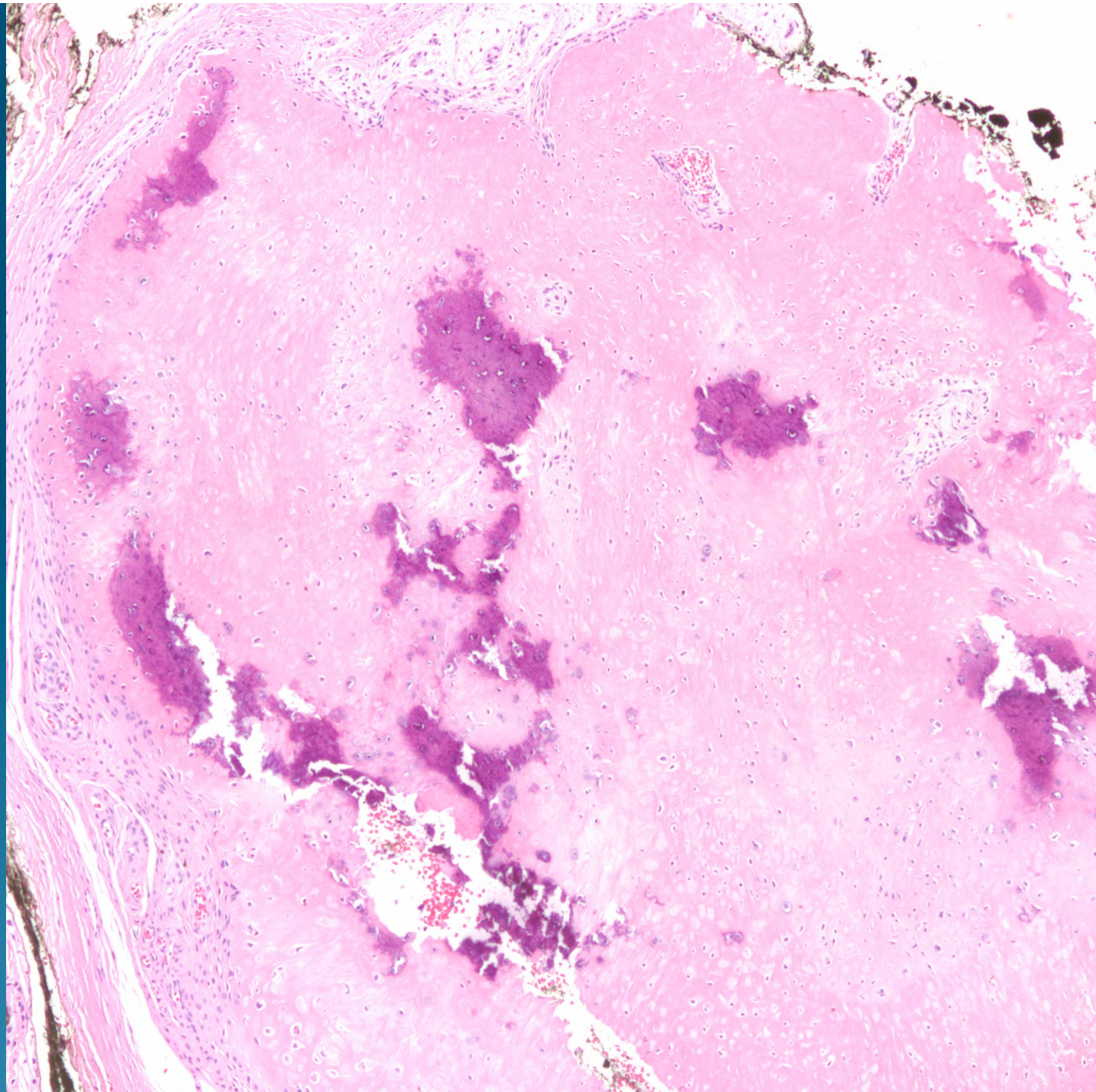
Tattoo arising with a seborrheic  
keratosis

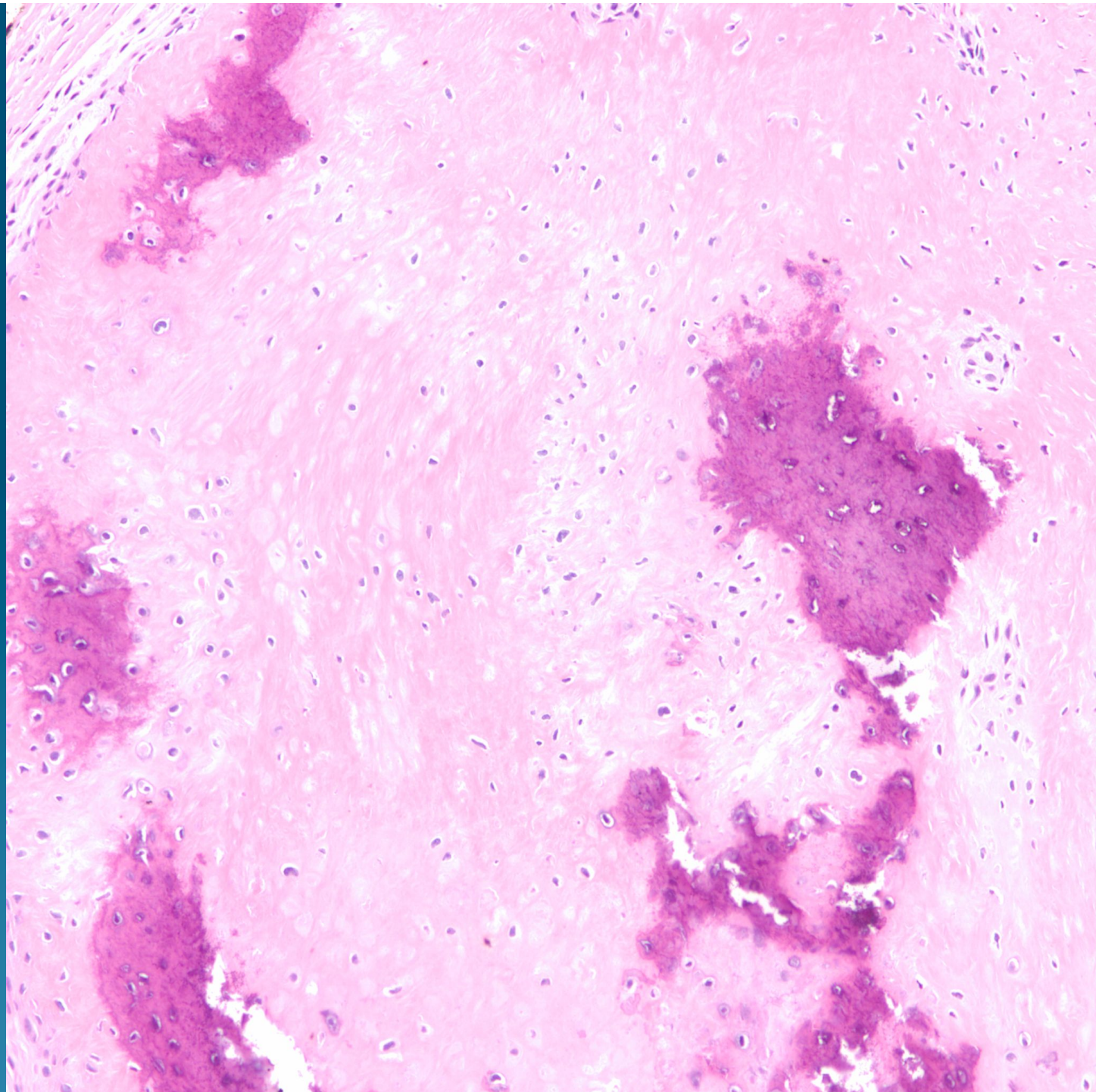
# Pearls

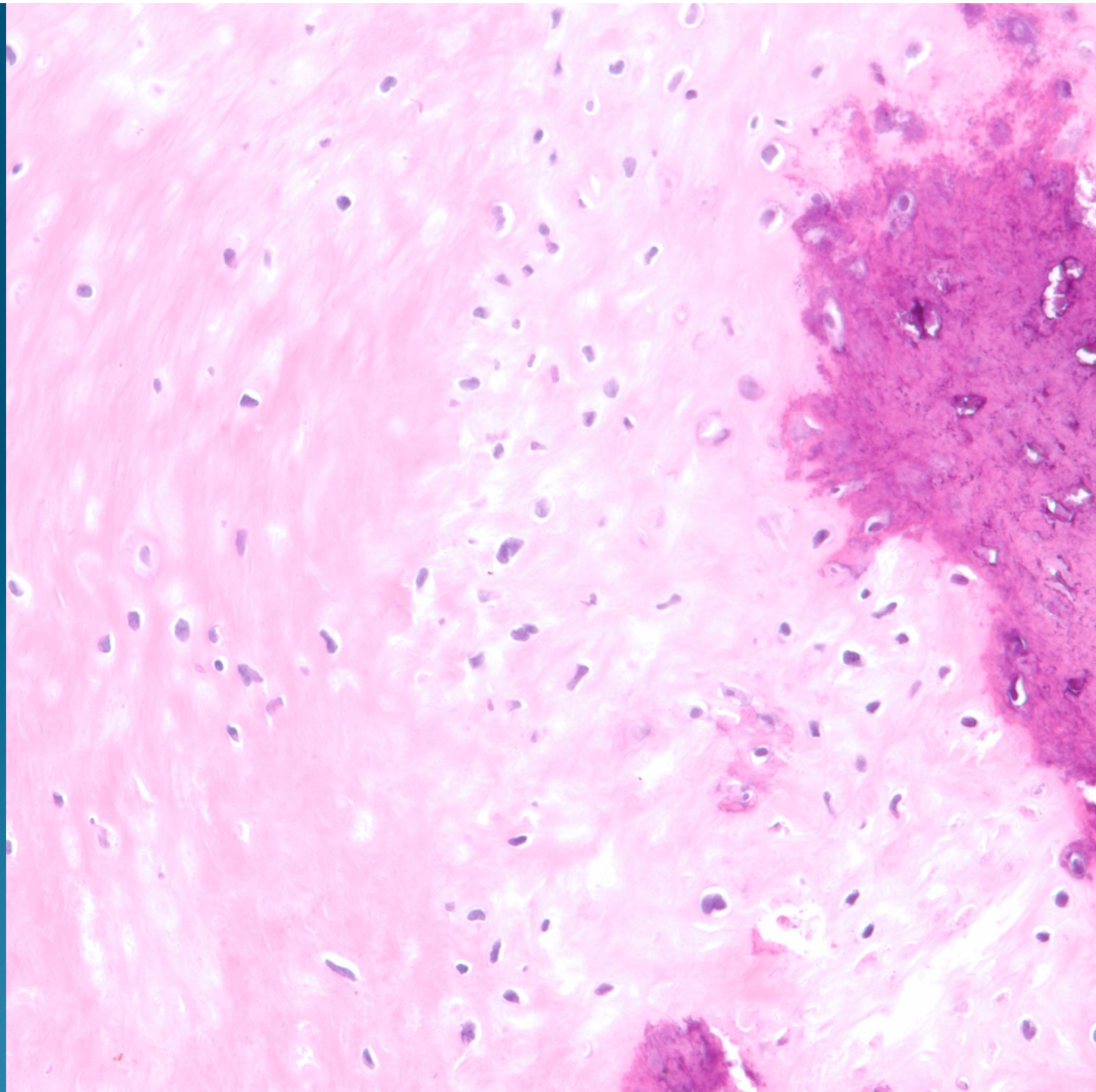


- Tattoo pigment identified by coarse granules both intra-and extra-cellular
- Occasionally other tissue reactions including granulomas, foreign body giant cells
- Rarely epithelial proliferations may be associated-may be coincidental







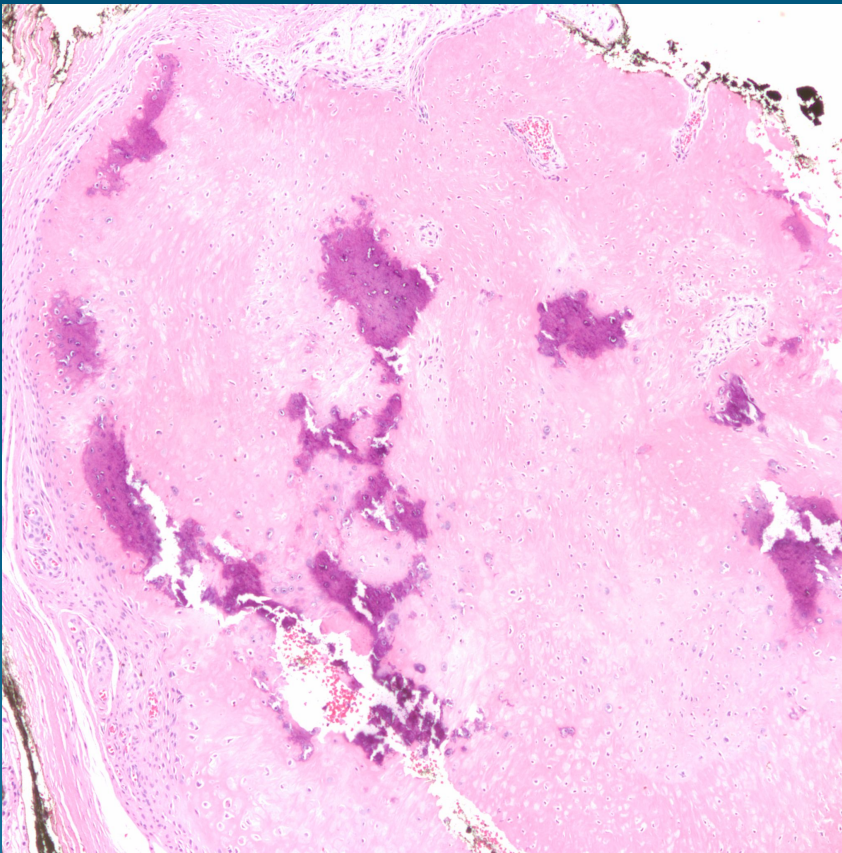


# What is the best diagnosis?

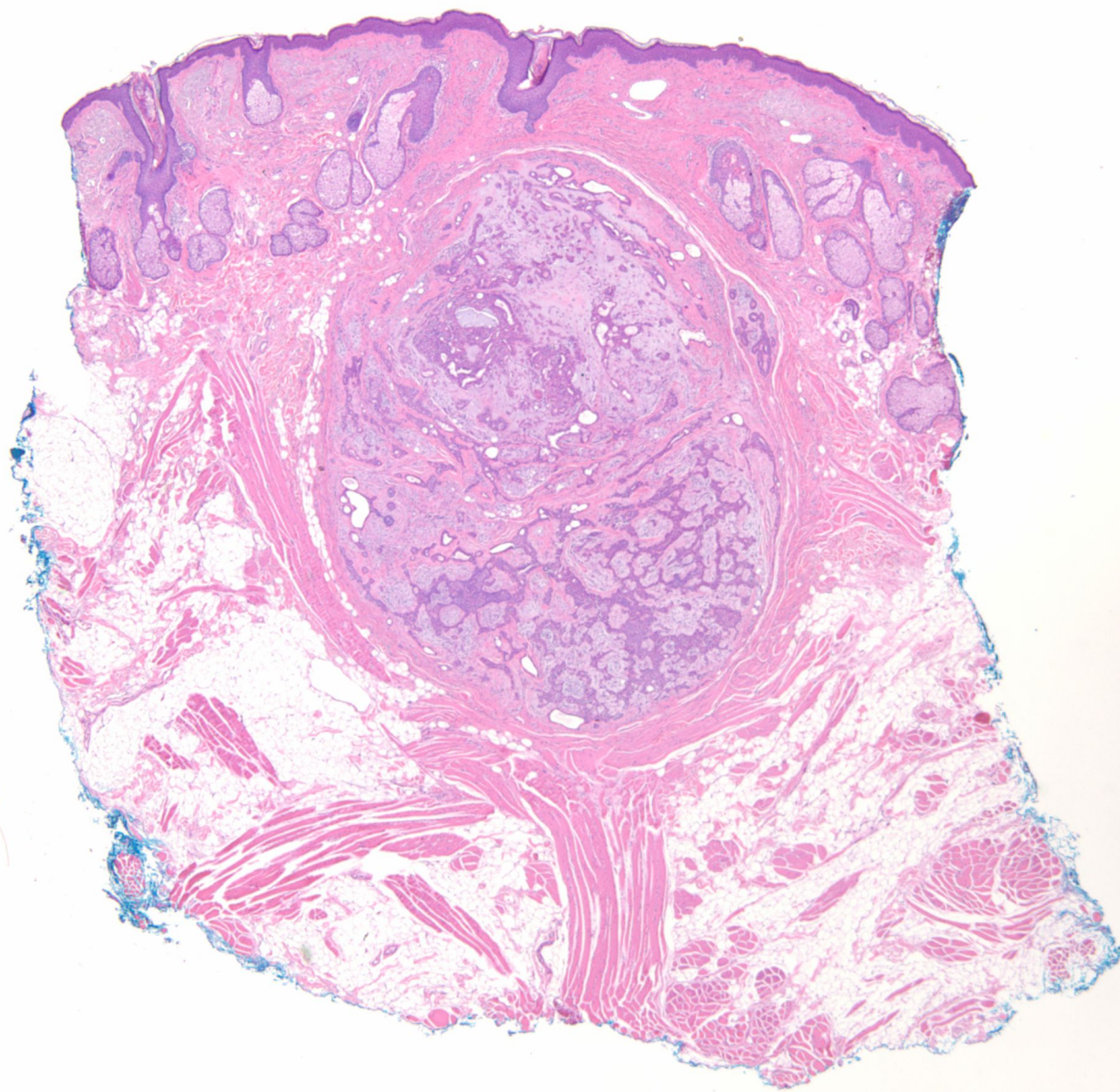
- A. Chondrodermatitis nodularis helices
- B. Osteoid osteoma
- C. Chondrosarcoma
- D. Ossifying fibromyxoid tumor
- E. Osteoma cutis

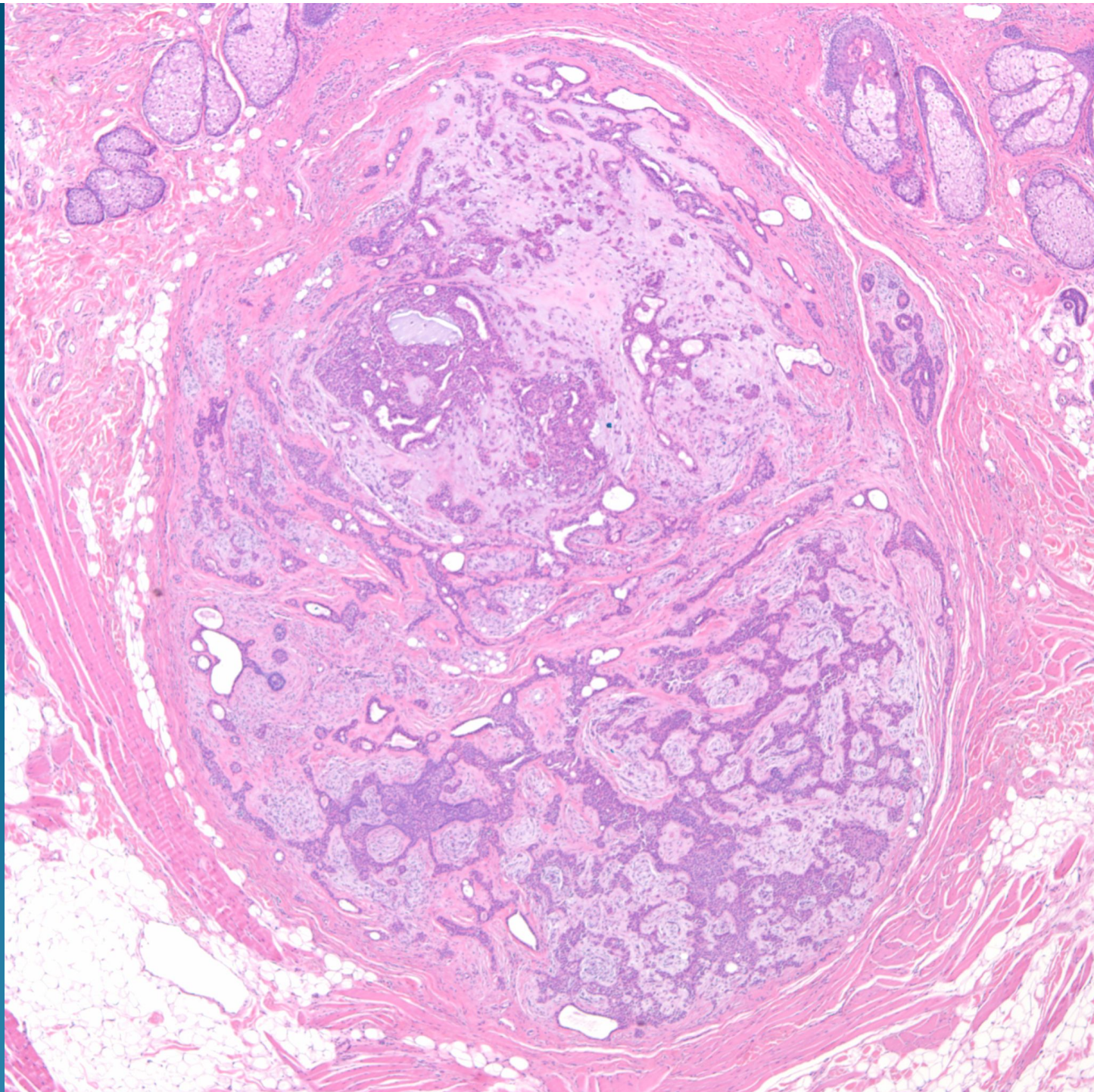
# Osteoma Cutis

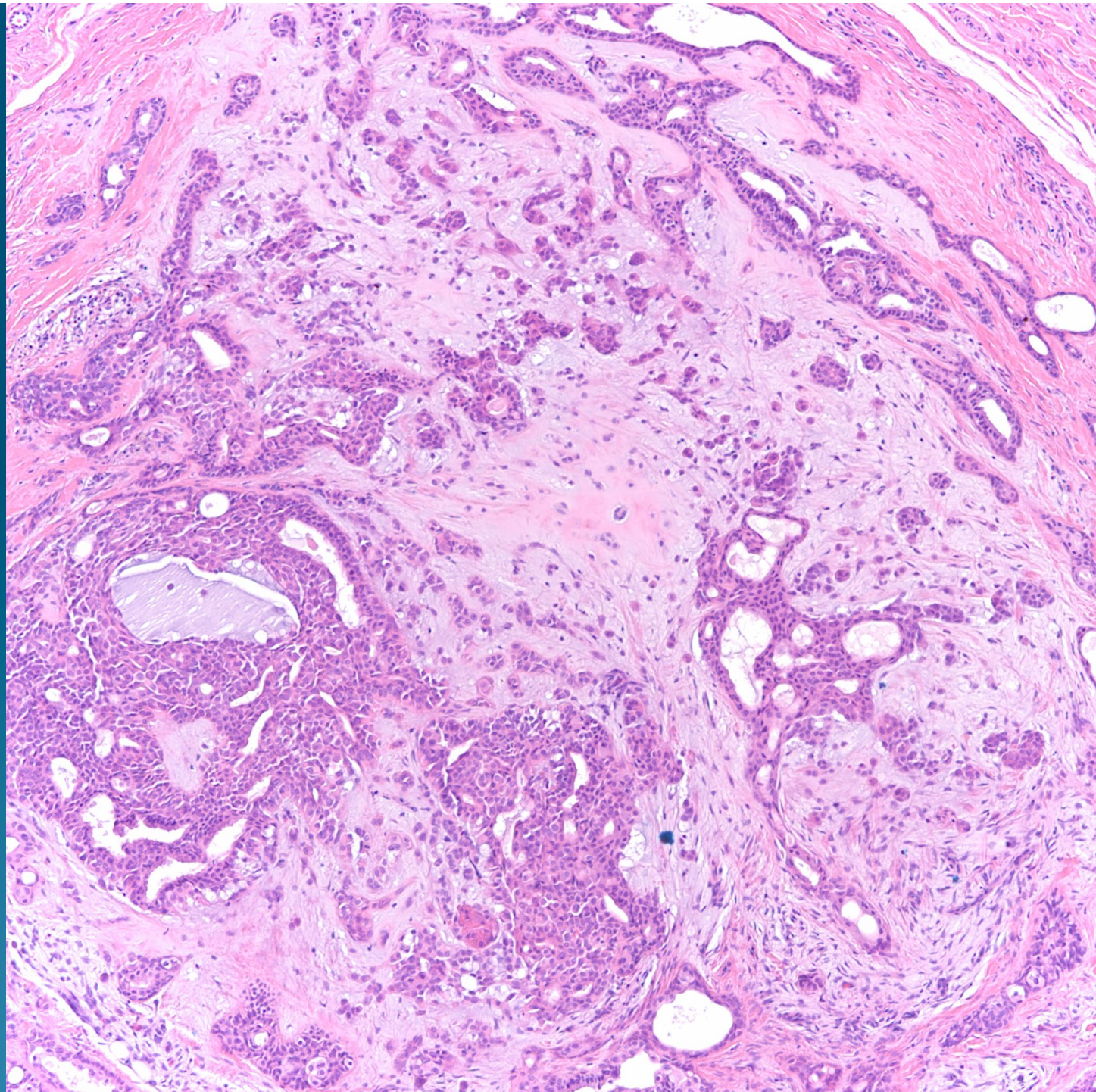
# Pearls

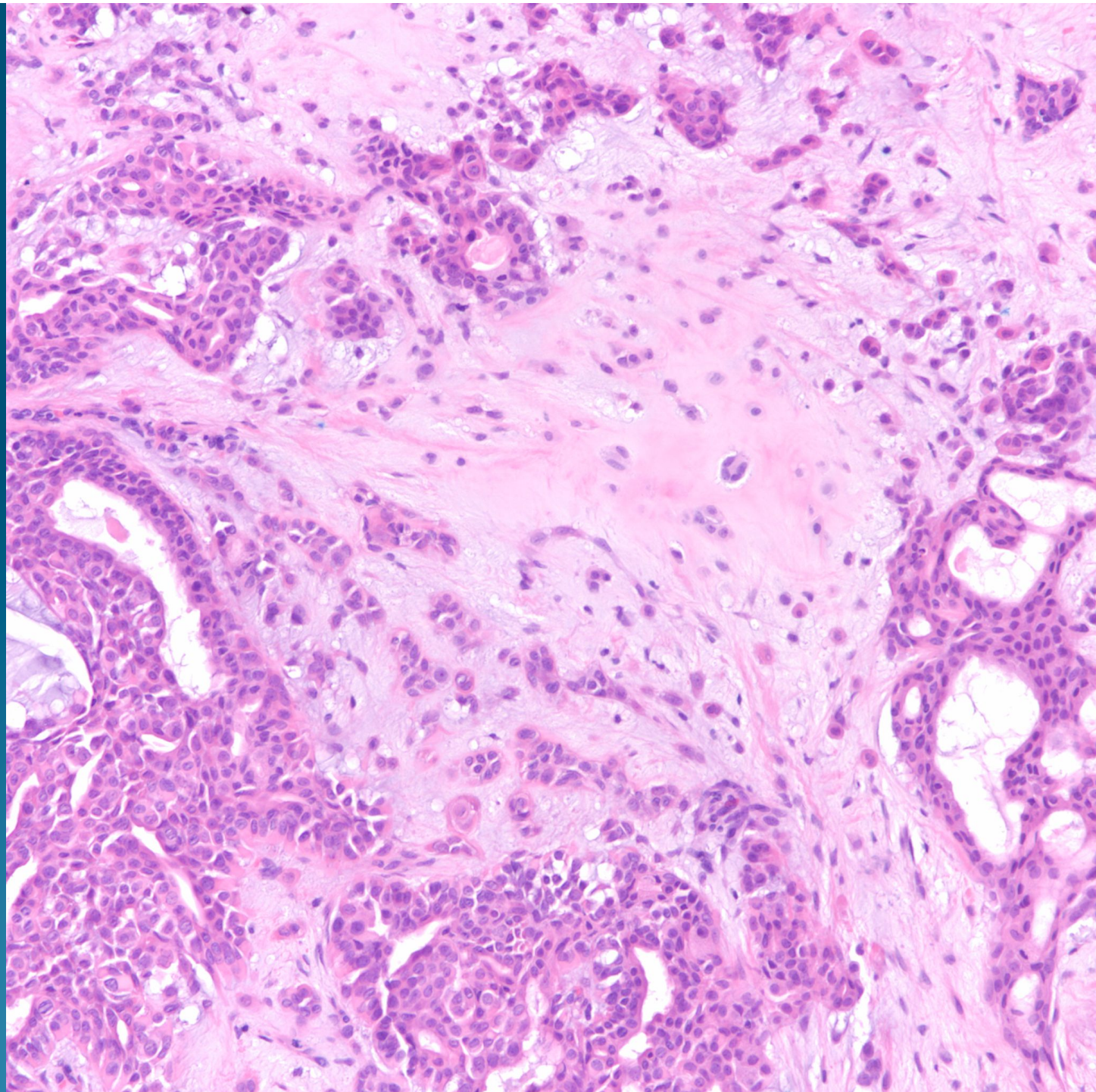


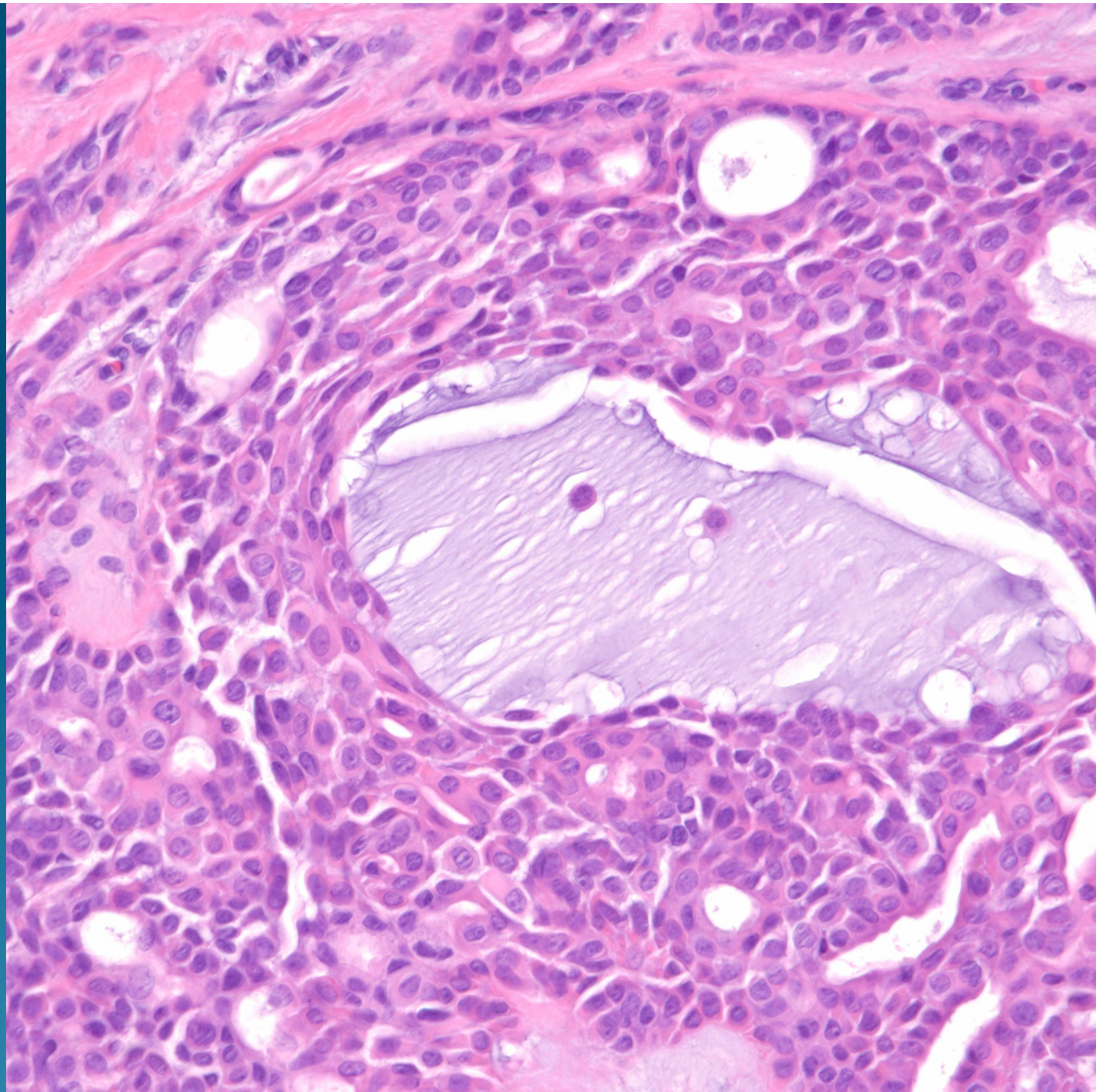
- Mature bone with varying degrees of ossification and calcification
- Histologically benign and usually circumscribed
- May see antecedent lesion such as epidermal cyst or hemangioma

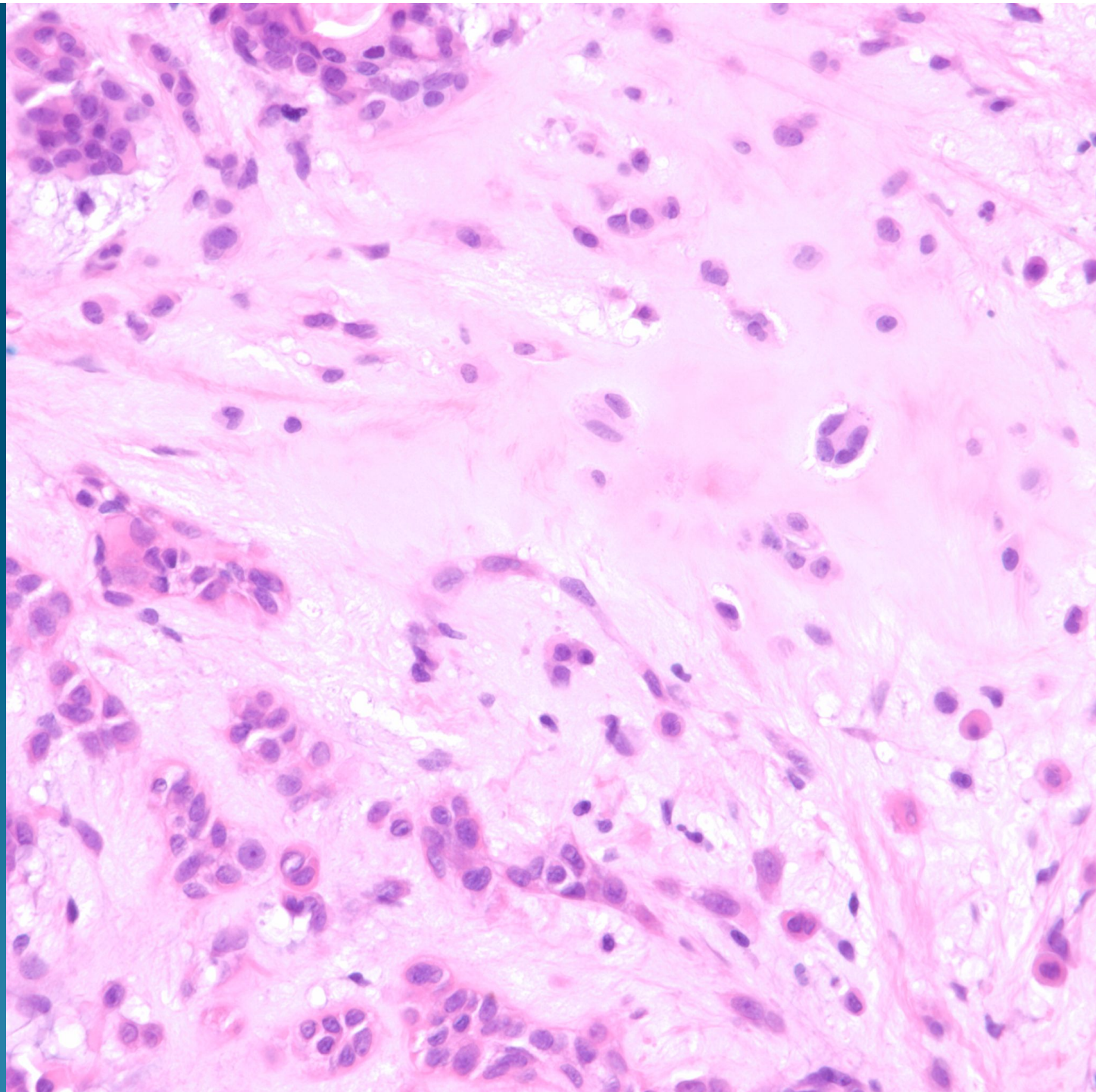












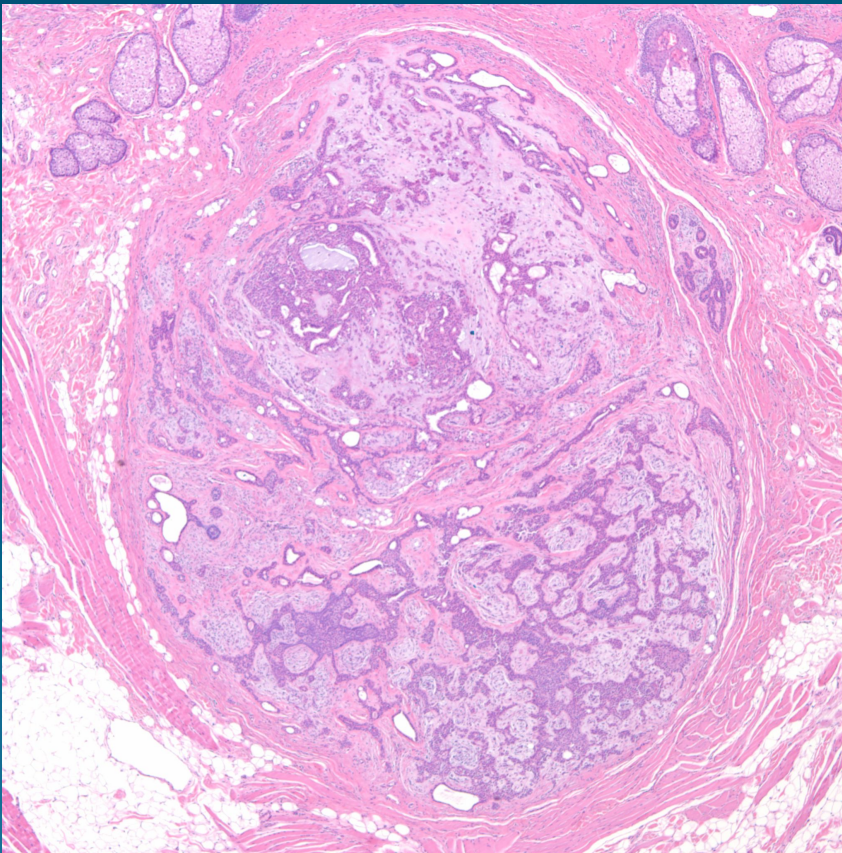
# What is the best diagnosis?

- A. Chondroid syringoma
- B. Eccrine spiradenoma
- C. Apocrine cystadenoma
- D. Nodular and cystic hidradenoma
- E. Accessory breast tissue

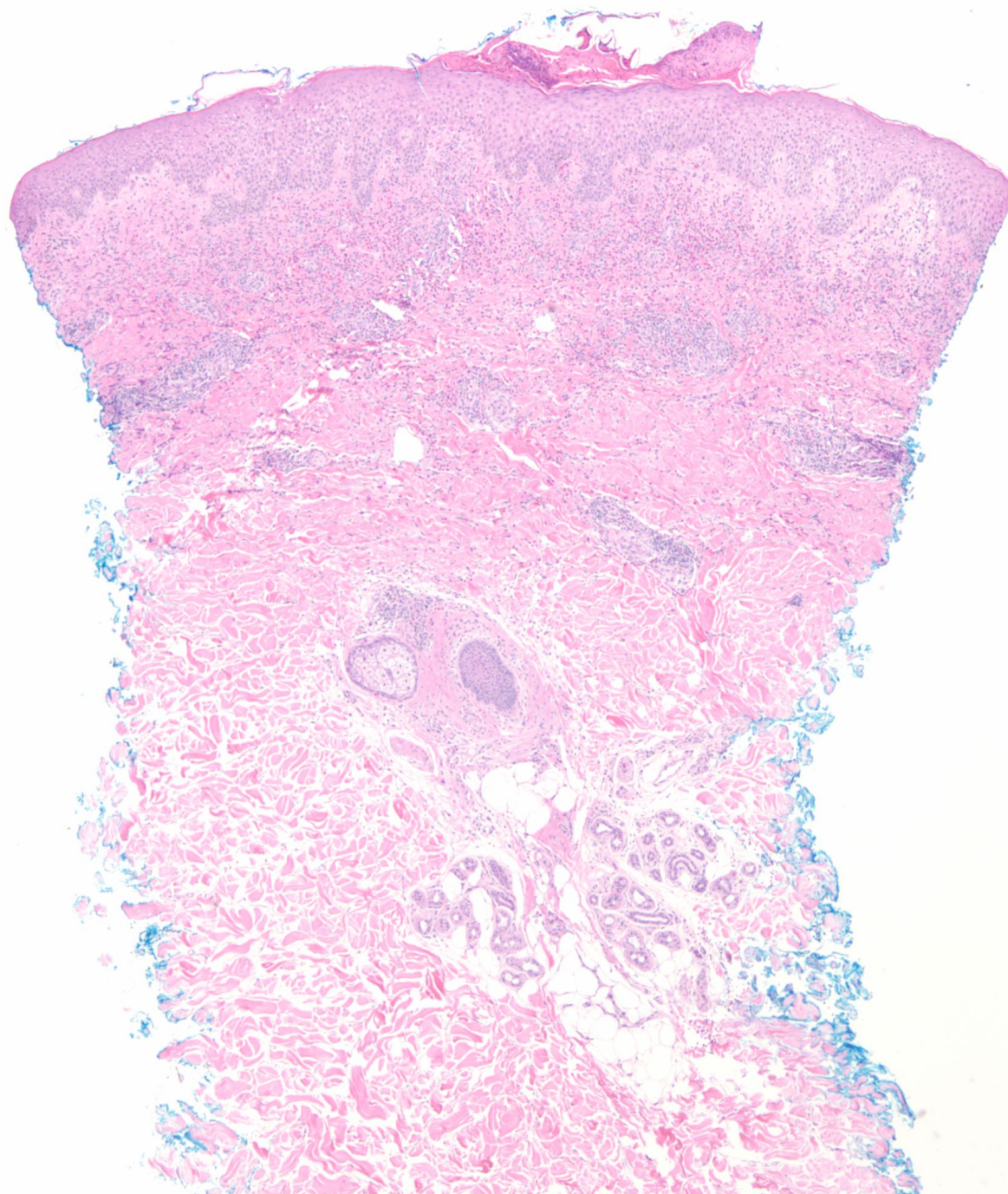
# Chondroid Syringoma

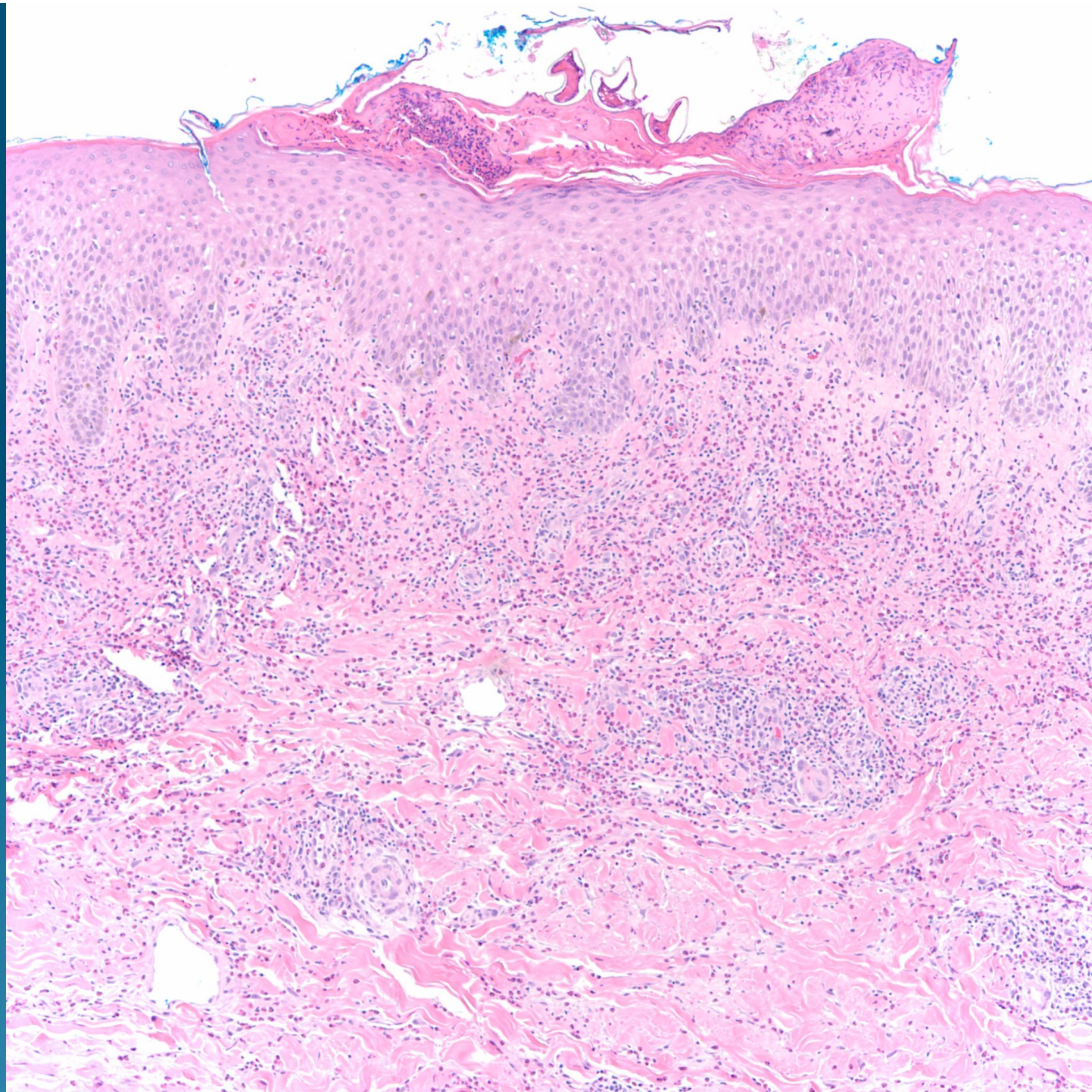
(Benign cutaneous mixed tumor)

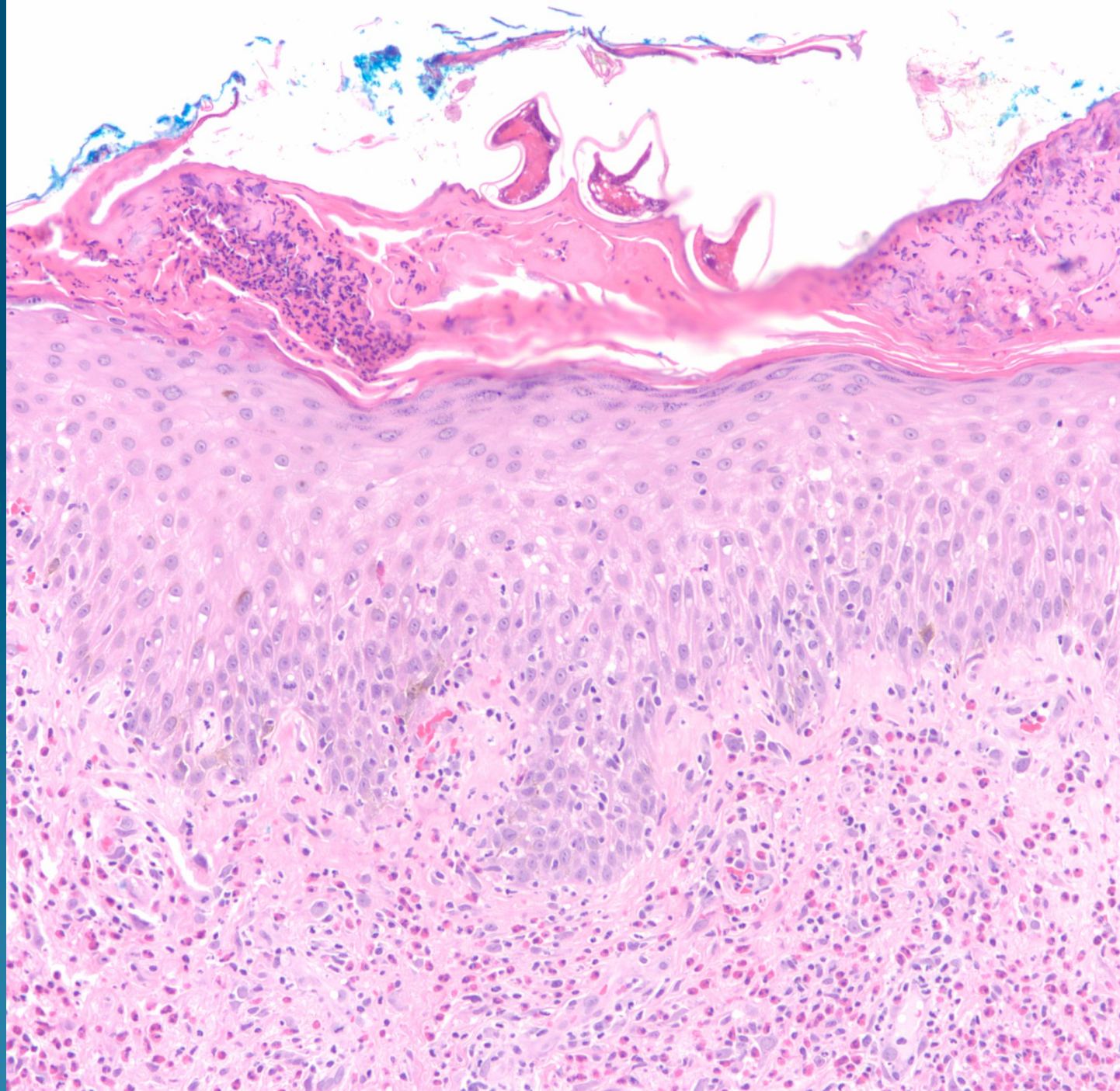
# Pearls

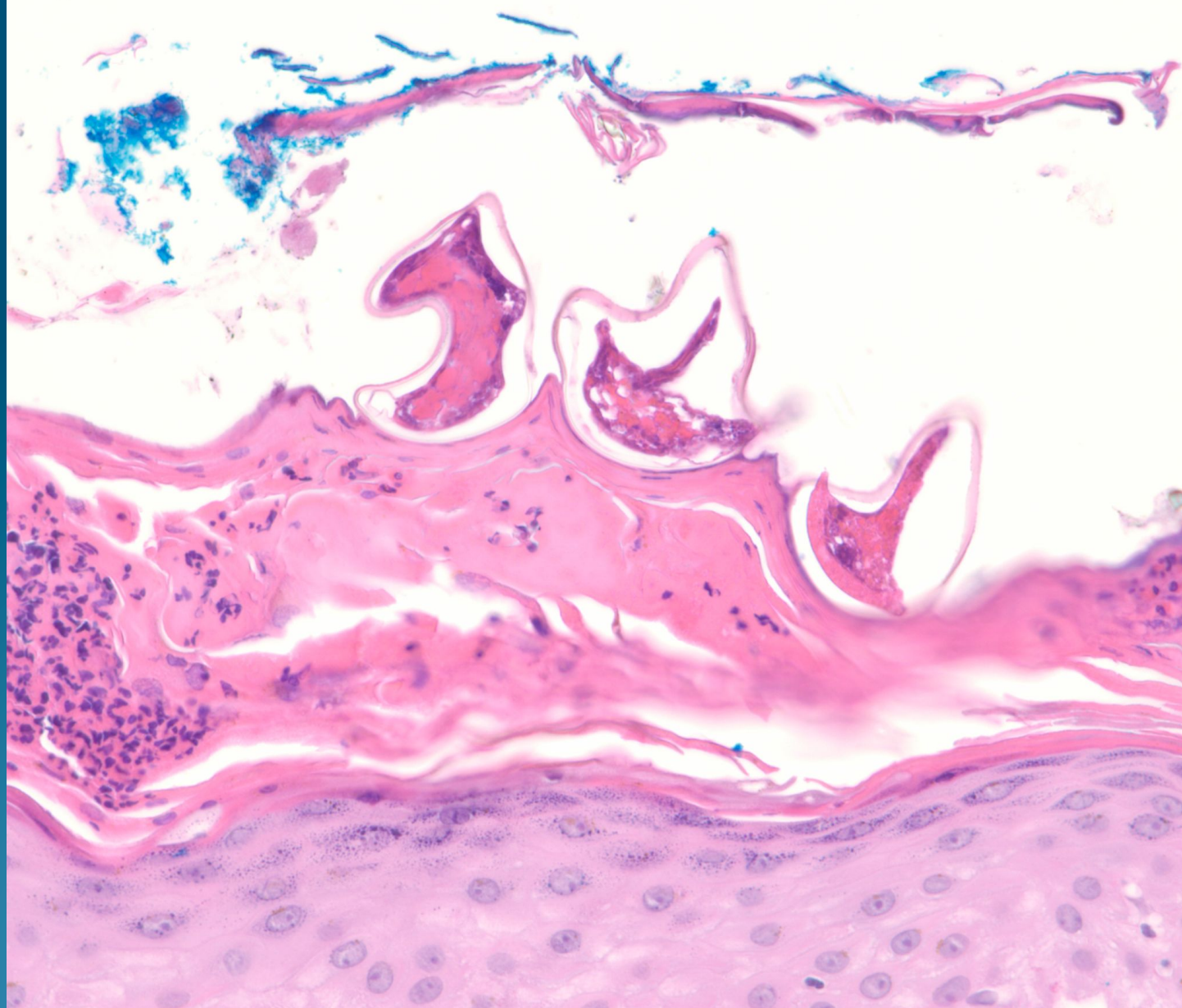


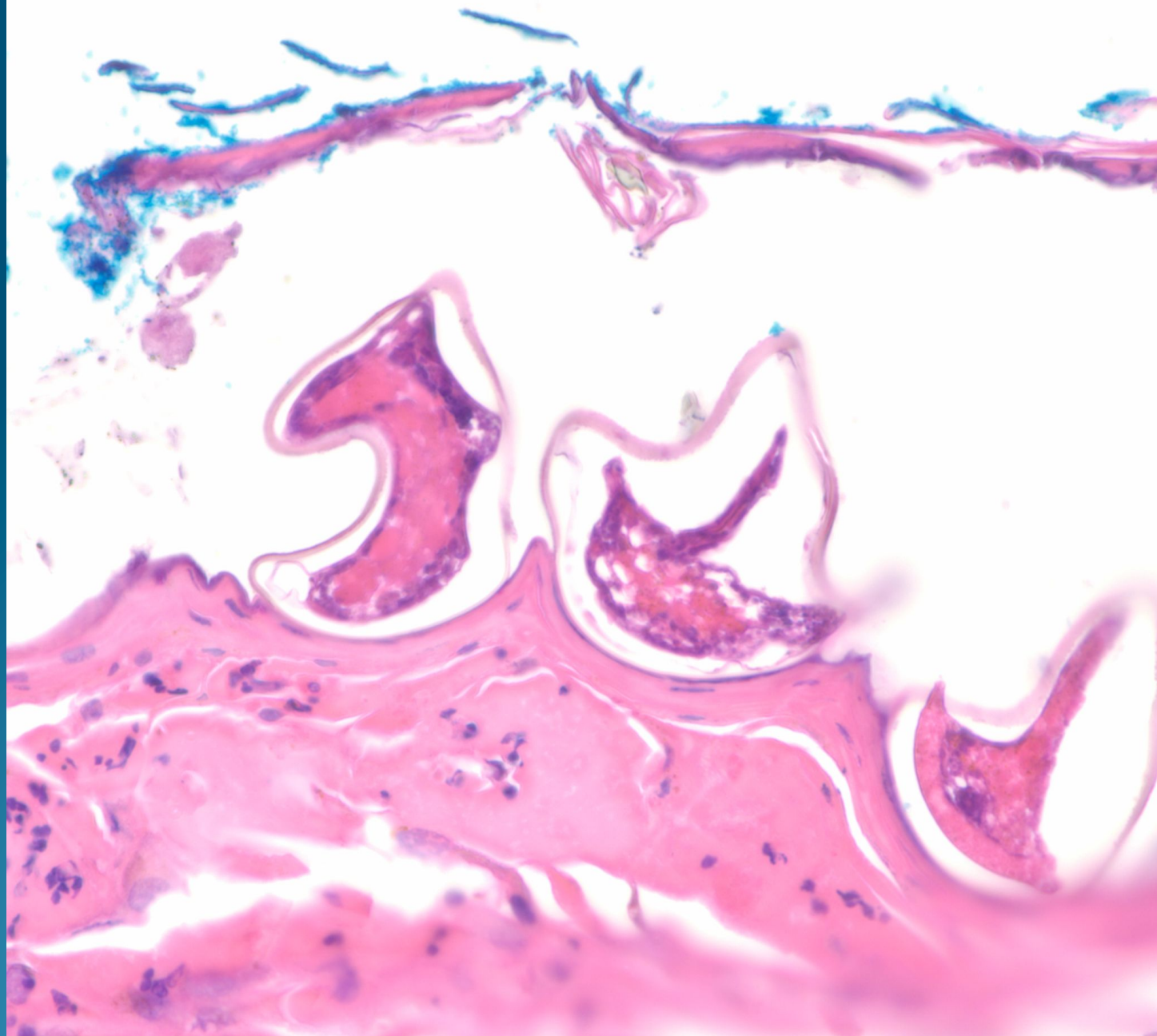
- Circumscribed dermal tumor with no epidermal attachment
- Varying solid and cystic components lined by squamous, apocrine, and eccrine epithelial cells
- Chondroid myxoid background of bluish hue









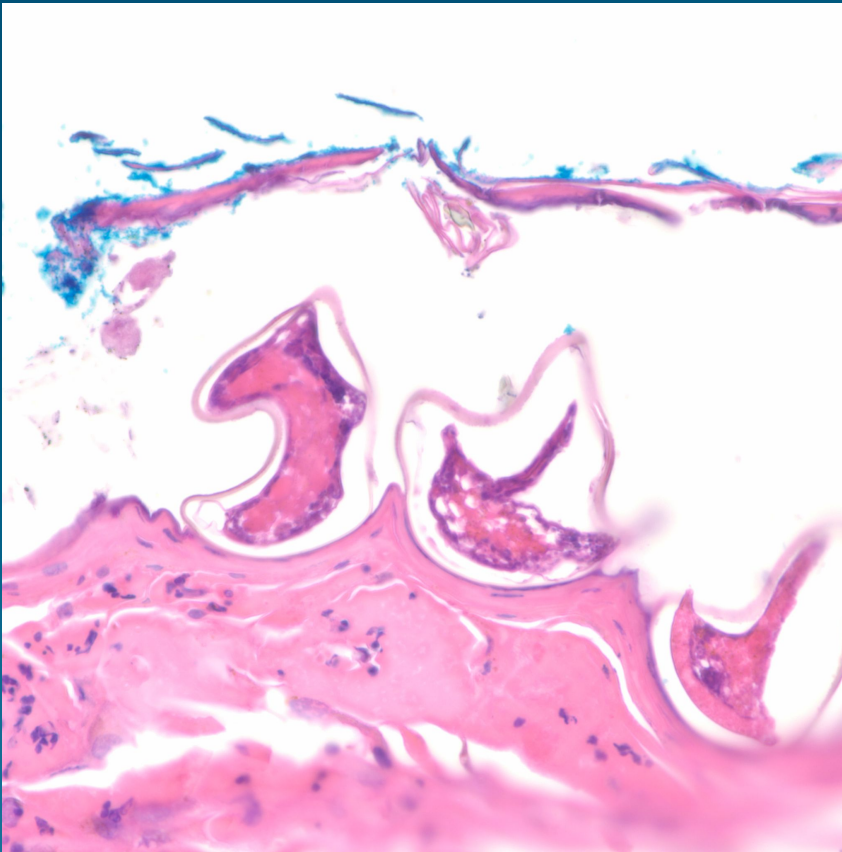


# What is the best diagnosis?

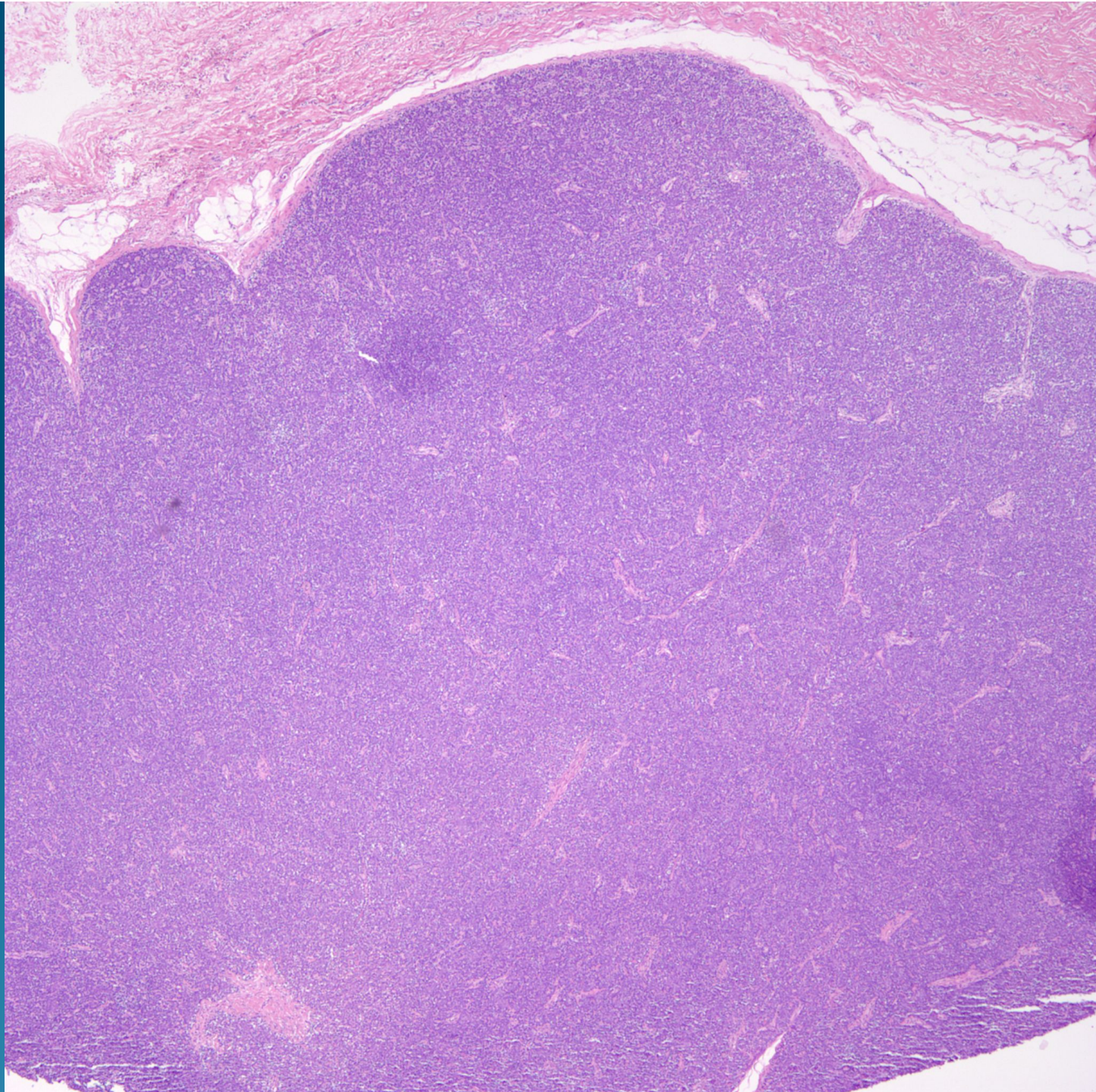
- A. Demodex
- B. Louse
- C. Scabies
- D. Bott Fly
- E. Lobomycosis

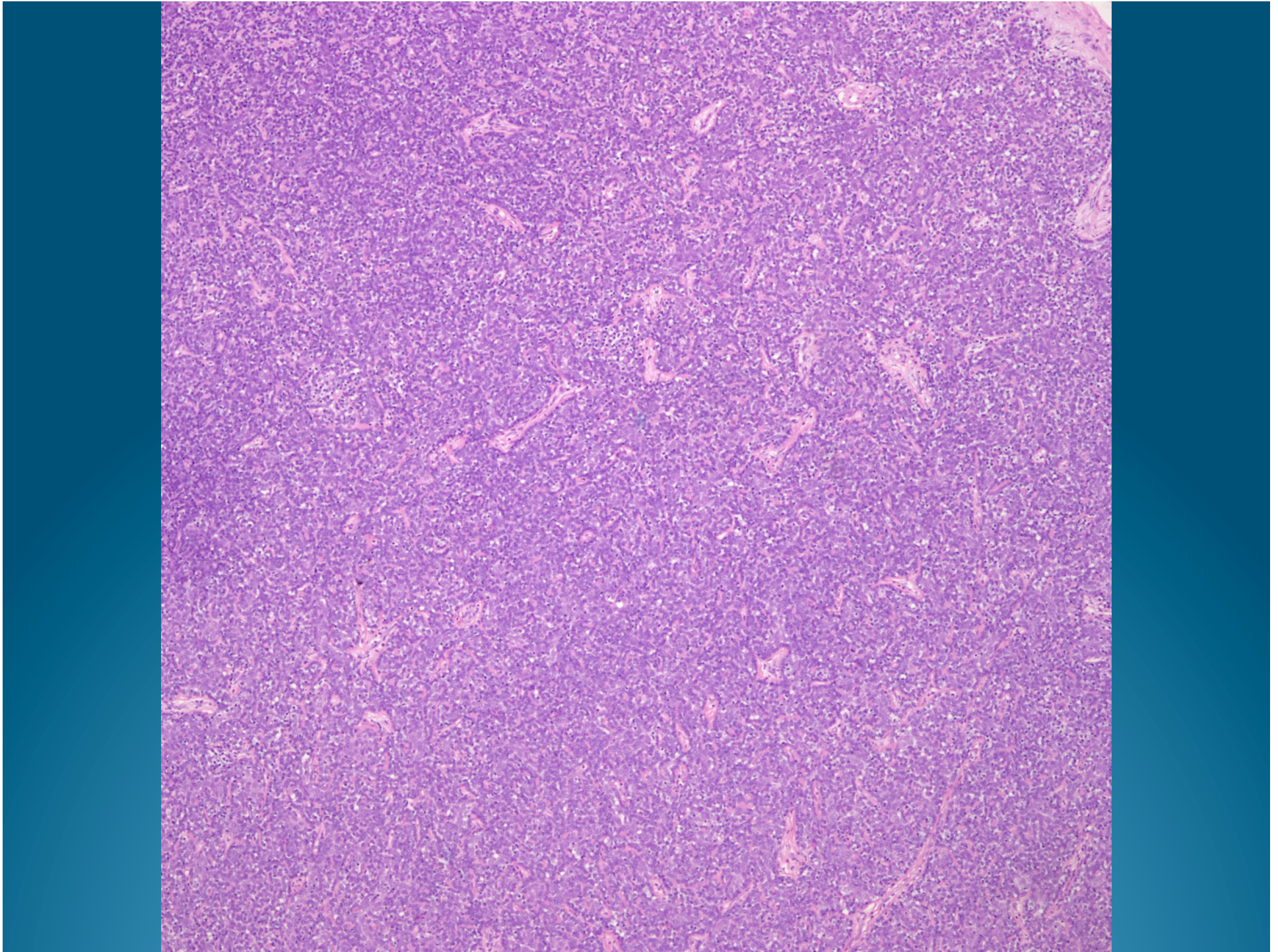
# Scabies

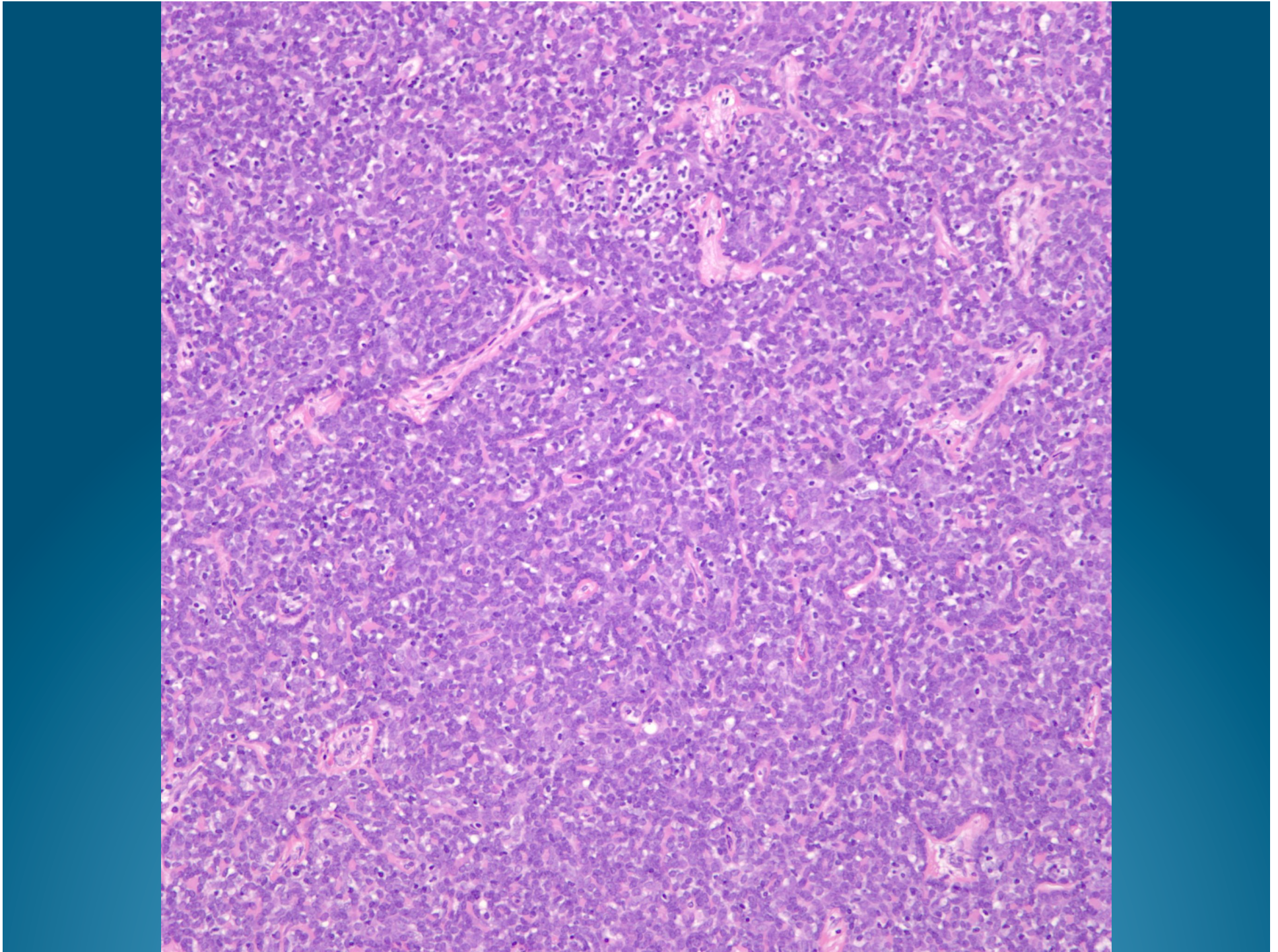
# Pearls

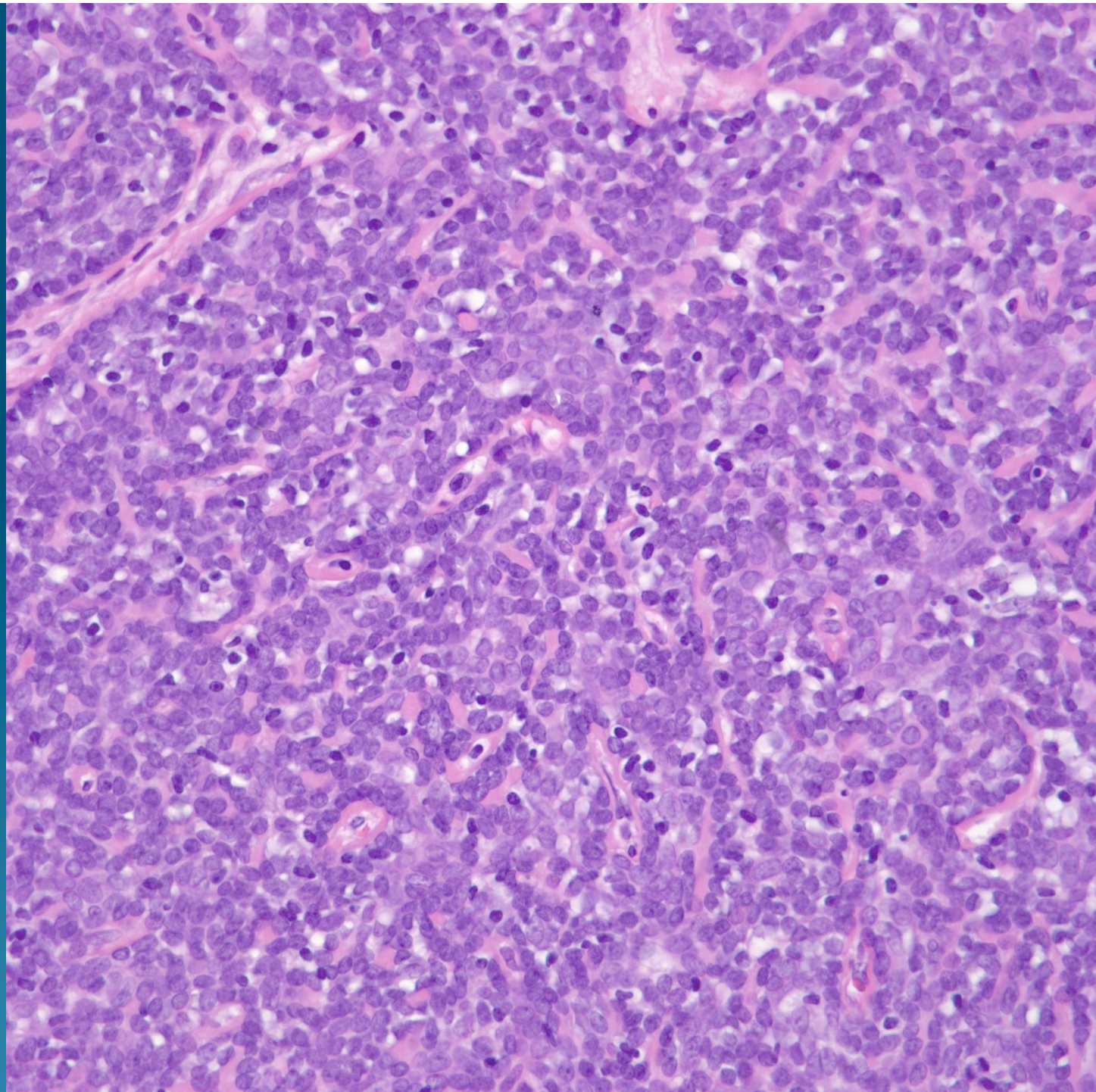


- Mite is only located in the stratum corneum
- Look for rigid cuticle
- May see scybula (feces)- this is sufficient for diagnosis
- Variable inflammatory response, occasionally a nodular collection of eosinophils







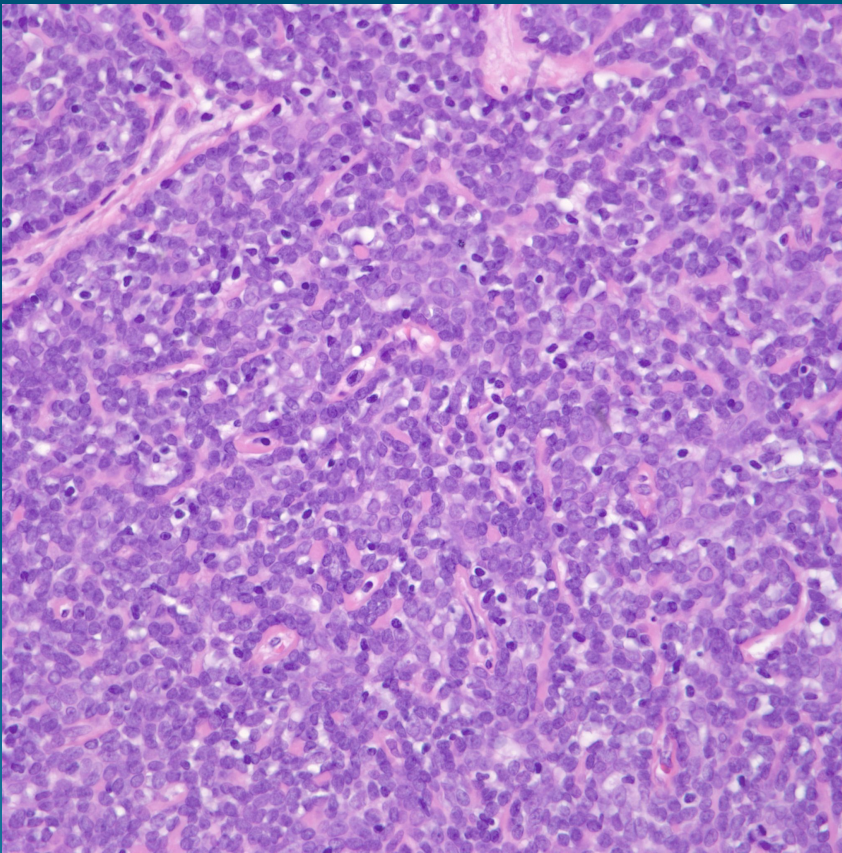


# What is the best diagnosis?

- A. Nodular hidradenoma
- B. Tricholemmoma
- C. Pilomatricoma
- D. Glomus tumor
- E. Eccrine spiradenoma

# Eccrine Spiradenoma

# Pearls



- Circumscribed dermal nodule, unattached to epidermis
- Small basaloid cells with minimal variation admixed with small lymphocytes
- Hyalinized basement membrane surrounding larger nests